
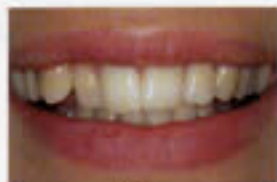

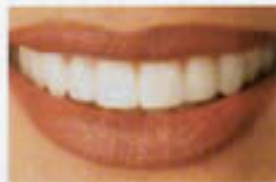*About the Cover, continued from page 6.*

This beautiful young woman was presented with misaligned maxillary anterior teeth. She declined a recommendation of orthodontic treatment. As an alternative, her goals were achieved with the placement of feldspathic veneers on teeth # 4-13, aligning the teeth and building in the appropriate anterior guidance.

Cosmetic dentistry by Dr. Sue Wendling, Lake Oswego, OR; ceramics by Marvin Staggs, PDR Laboratory, Salem, OR; photography by Legacy Fine Portraits, Vancouver, WA. 



*before*



*after*

